Journal of Engineering and Science Research 4 (5): 11-17, 2020
e-ISSN: 2289-7127

DOI: 10.26666/rmp.jesr.2020.5.2

# Fully-automated Segmentation for MRI Human Spine Images using Thresholding Methods

**Aqilah Baseri Huddin and Nor Aqlina Binti Abdul Halim**

Center for Integrated Systems Engineering & Advanced Technologies (INTEGRA), Faculty of Engineering & Built Environment, Universiti Kebangsaan Malaysia
*Corresponding Author: aqilah@ukm.edu.my

**Abstract:** Computer Aided Diagnosis (CAD) in MRI image processing could assist experts in detecting the abnormality of human spine image efficiently. The manual process of detecting abnormality are tedious, and hence the use of CAD in this field is useful to increase the diagnose's efficiency. Segmentation method is one of the important process in CAD that could affect the accuracy of the overall diagnosis of MRI spine images. There are various segmentation methods commonly used in CAD. One of the methods is segmentation using thresholding. Thresholding approaches divide area of interest by identifying the threshold values that can separate the the image into desired levels of grayscale based on its pixel's intensity. This study focusses on investigating the optimum approach in segmentating lumbar vertebrae on the MRI images. The steps involved in this study include pre-processing (normalization), segmentation using local and global thresholding, neural network classification and performance measurement. 20 images are used to evaluate and compare the segmentation methods. The effectiveness of segmentation method is measured based on the performance measurement technique. This preliminary study shows that, local thresholding outperforms the global thresholding approach with accuracy of 91.4% and 87.7%, respectively.

**Keywords:** *CAD; MRI; image processing; segmentation; otsu*

## 1. INTRODUCTION

A healthy human spine is important to provide support to the body. The human spine consists of five main sections which are cervical vertebrae, thoracic vertebrae, lumbar vertebrae, sacral vertebrae and coccyx vertebrae. Overall there are about 33 vertebra in combination of five main sections. Each of the vertebrae is separated and cushioned by an intervertebral disc. However, human might be suffered from spinal diseases due to many factors, such as wrong posture, accident or aging. Among spinal diseases are herniated disks, slipped vertebra, fractures and deformities. These diseases are difficult to diagnose externally. Lumbar vertebrae are important to carry weight of the body and much larger in size to absorb stress of lifting and carrying heavy object. However, it was reported that 95% of herniated disks occur at the lower lumbar vertebrae (Jordon, Konstantinou and O'Dowd, 2009). Thus, in this study, we focusses in segmenting and classifying the intervertebral disk in lumbar vertebrae (L1 to L5) of spine MRI.

One of the medical imaging modality used by the experts to diagnose these diseases is Magnetic Resonance Imaging (MRI). MRI procedure provides images of the internal parts of body such as organs and bones and hence the experts are able to use these images to diagnose the diseases. MRI scans are divided into two categories, T1 and T2 weighted scans. T1-weighted scans produces dark image for any part filled with water and brighter images for soft tissues with high fat concentration. Whilst, T2-weighted scans produces dark images for soft tissues with high fat concentration and brighter images for any part filled with water.

Computer Aided Diagnostic (CAD) system for MRI images processing could assist specialists in detecting abnormalities of the human spine efficiently. CAD system can analyze and improve the accuracy of diagnosis by increasing sensitivity in the detection and characterization

**Corresponding Author:** Aqilah Baseri Huddin, Center for Integrated Systems Engineering & Advanced Technologies (INTEGRA), Faculty of Engineering & Built Environment, Universiti Kebangsaan Malaysia. Email: aqilah@ukm.edu.my

(Doi, 2005). With the emerging technology nowdays, the research in the automated image analysis for detection and segmentation of vertebrae utilizing CAD system has become demandly popular. However, to achieve a fully automated detection and segmentation system is a challenging task. Most previous work such as in (Rangayyan, Deglint and Boag, 2006) requires prior information of vertebrae location. Commonly, there are five important processes in CAD system, which are pre-processing, segmentation, extraction, classification and performance measurement (Michopoulou, 2011).

Segmentation process in CAD plays an important role to get the high precision image for diagnosis. Segmentation divides MRI images into desired regions, with the aim to enhance the targeted region of interest in the image. However, to develop a segmentation algorithm that is efficient is very challenging. MRI images have low-contrast and non-uniform background. This affects the efficiency of the segmentation process and thus contribute to the deficiency in diagnosis result. The artifacts and noises that are caused by physiological motions during the acquisition process degrades the quality of the images (Hirokawa *et al.*, 2008). In addition, the problem in determining the position of vertebra spine also affect the effectiveness of the segmentation method. This is because a spine have a complex composition of fat, water, soft tissue and cartilage. In order to solve that, we are motivated to investigate segmentation methods that usually use for detecting the abnormalities of MRI spine images.

Several segmentation methods for MRI human spine has been proposed. Most work requires manual intevention to locate the center of the spinal cord before the segmentation is done (Hoad *et al.*, 2001; Rangayyan, Deglint and Boag, 2006; Michopoulou *et al.*, 2009; Barbieri *et al.*, 2015). The manual process is time consuming for huge amount of MRI spine cases. There are also work proposed for a fully automatic MRI vertebrae segmention such as work by (Peng *et al.*, 2005) and (Chevrefils *et al.*, 2009). Segmentation of MRI images can be performed based on the pixel information of the images, such as superpixel technique (Barbieri *et al.*, 2015), watershed techique (Roberts, Gratin and GH. Whitehouse, 1997; Bazila and Mir, 2014) and thresholding (Barbieri *et al.*, 2015). Another approach is based on the texture analysis of the MRI images (Chevrefils *et al.*, 2009).

In this paper, a simple yet effective method for segmentation, a thresholding method is studied. Two thresholding approaches which are global and local are evaluated and compared based on the classification performance.

## 2. MATERIALS AND METHODS

In this paper, 50 MRI spine images were chosen as dataset to perform segmentation using severeal thresholding techniques. These images are collected and contributed by our collaborators in Department of Radiology, HUKM. The chosen images are limited to only sagittal views and focusses on the lumbar part of the spine.

Commonly, there are five important processes in CAD, which are pre-processing, segmentation, extraction, classification and performance measurement as depicted in (Figure 1). Each of the images will undergo these five processes, where the details of each process are explicitly explained in this section.

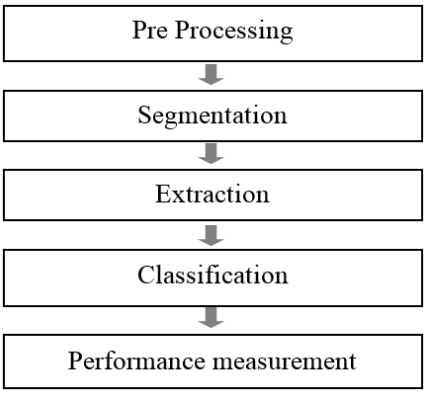


Figure 1. Block diagram for processes in CAD

### *2.1 Pre-processing*

In pre-processing, normalization technique is applied. Normalization process changes the range of pixel intensity values, without changing the information contain in the images. Normalization technique is sometimes called as dynamic range expansion. The purpose of the dynamic range expansion in application of gray-scale image is usually to bring the image into a specified range so that a consistent

pixel-range within all the images is achieved. The normalization of grayscale image is performed linearly according to (1).

$$I_N = \frac{I - I_{min}}{I_{max} - I_{min}} \quad (1)$$

where $I$ is the pixel value of original image, $I_N$ is the pixel value of normalized image, $I_{min}$ and $I_{max}$ is the minimum and maximum pixel value in the image respectively.

The acquired MRI spine image has color of grayscale, which has dynamic range of pixel intensity. Normalization process changes the pixel intensity values to have in the range between minimum and maximum of [0,1]. The minimum range is zero in which represents the black color while the maximum range is one in which represents the white color with any fractional value within that numerical range.

Figure 2 shows the histogram of an image before and after applied the normalization process. The figures show that after the normalization, the pixel image at any fractional value are existed within that numerical range value. However, the image of the MRI spine remains the same.

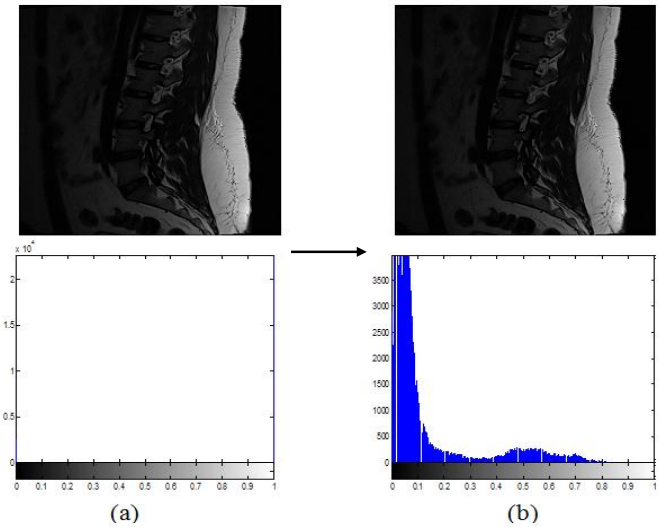


*Figure 2. MRI image (a) histogram of original image (b) histogram of a normalized image*

*2.2 Segmentation*

The thresholding technique is one of the simplest yet effective method for segmentation and has been widely used in many applications including for medical images. The thresholding techniques is used to separate an image into the desired number of regions based on the distribution of gray levels in the image. For an example, a grayscale image (i.e image with pixel values from 0 to 255) may be converted into a binary image (i.e image with pixel value 0 or 1) by segmenting it into two regions of colorscale e.g black and white.

This is achieved by applying a threshold value that can use to separates the image's pixel values into those two regions. In other word, the pixel value that is less than the threshold value is set as 0 (black), and any pixel value that is more than the threshold value is set to 1 (white). The thresholded image $g(x, y)$ of an image with pixel value, $p(x, y)$ may be expressed as in (2):

$$g(x, y) = \begin{cases} 1 \text{ for } p(x, y) > t \\ 0 \text{ for } p(x, y) \leq t \end{cases} \quad (2)$$

where $t$ is the threshold value.

The threshold value is determined by optimizing the specified criterion function such as minimizing the intra-class variance in Otsu's method, or uses the statistical information of the images such as entropy, mean and standard deviation to separate the object from the background (Chen *et al.*, 2018). Thresholding techniques can be applied globally or locally to an image. Global thresholding applies a single thresholding value, $t$ to an entire image. Whereas, a local thresholding technique applies different threshold values for different region of an image (Senthilkumaran and Kirubakaran, 2014).

2.2.1 Global Thresholding – Otsu Method

Thresholding using Otsu is one of the common technique in segmenting images. In Otsu's method, the segmenting is done on the basis of the distribution of gray level in the image. In a 2D grayscale image, it contains $N \times N$ pixels that each has gray level, $i$ range from $[1, \ldots, L]$. Thus, the number of pixels with gray level $i$ is denoted as $f_i$. The probability $p_i$ of gray level $i$ in an image can then be found using (3):

$$p_i = \frac{f_i}{N} \quad (3)$$

In Otsu's thresholding, the aim is to find a threshold to separate between classes by minimizing the between-class variance. In the case of two-level Otsu thresholding, the pixels in the image are divided into two classes, $C_1$ and $C_2$. Here, the first class, $C_1$ contains gray levels of $[1, \dots, t]$ and the latter class, $C_2$ contains gray levels of $[t+1, \dots, L]$. To find the threshold value, $t$, the Otsu method calculates the between-class variance, $\sigma_B^2$ using (4):

$$\sigma_B^2 = \omega_1(\mu_1 - \mu_T)^2 + \omega_2(\mu_2 - \mu_T)^2 \quad (4)$$

where, $\omega_1(t)$ and $\omega_2(t)$ are the sum of gray level probability distribution in classes $C_1$and $C_2$, respectively. $\mu_1$and $\mu_2$ are the means for classes $C_1$and $C_2$, respectively. $\mu_T$ is the mean intensity for the whole image.

Otsu method recursively finds the optimal threshold value, $t$ so that the between-class variance $\sigma_B^2$ is minimized. This algorithm can also extend to a multi-level Otsu thresholding. Suppose the image is thresholded into $M$classes. Otsu method applies the above equation to find $M-1$ thresholding values, $\{t_1, t_2, \dots, t_{M-1}\}$ to segment an image into $M$ classes. Figure 3 shows resulting thresholded MRI images using (a) 2-level, (b) 3-level, (c) 4-level, (d) 5-level (e) 6-level and (f) 7-level Otsu thresholding method. In this study, it was observed that 6-level thresholding improved the physical appearance for lumbar vertebrae. Figure 3 shows resulting thresholded MRI images using (a) 2-level, (b) 3-level, (c) 4-level, (d) 5-level (e) 6-level and (f) 7-level Otsu thresholding method. In this study, it was observed that 6-level thresholding improved the physical appearance for lumbar vertebrae.

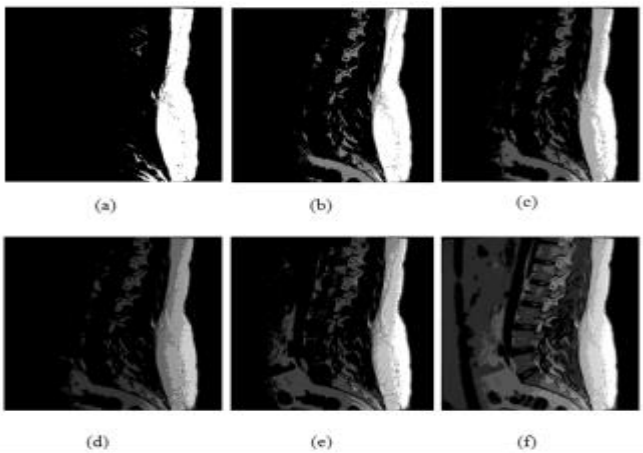


Figure 3. Tresholded MRI images using (a) 2-level, (b) 3-level, (c) 4-level, (d) 5-level (e) 6-level and (f) 7-level Otsu

2.2.2 Local Thresholding – Ni-black Method

If an image has non-uniform background, a single value of threshold may not be suitable to apply to an entire image for segmentation. A thresholding algorithm that adaptive to a small region may be used. This is also known as local thresholding method. One of the method is Ni-Black algorithm, where the algorithm determines the threshold value based on the local mean and the local standard deviation over a specific window size (Rais, Hanif and Taj, 2004).

In Ni-Black algorithm, the local threshold, $t$ at any pixel $(i,j)$ is found by using (5).

$$t(i,j) = m(i,j) + k\sigma(i,j) \quad (5)$$

where, $m(i,j)$ and $\sigma(i,j)$ are the mean and variance of the local pixel, respectively. Whereas, the value $k$ in the equation is the fixed weight that is used to control the effect of the standard deviation upon noise in the background (Rais, Hanif and Taj, 2004; Senthilkumaran and Kirubakaran, 2014).

*2.3 Features Extraction*

The shape features of the detected region are used for classification to classify them as vertebrae or the background. Figure 4 shows an example of one of the detected 'vertebrae' resulted from the thresholded image using Ni-black local thresholding algorithm.

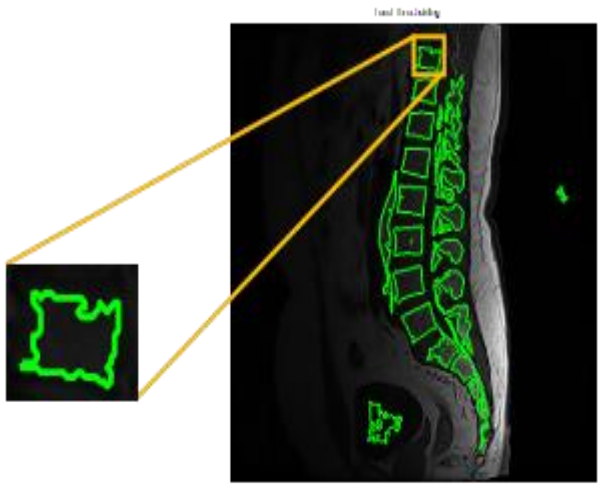

Figure 4. Detected vertebrae region

The shape features such as the area, perimeter, centroid and the diameter of each of the region are extracted using the formulae as in Table 1.

Table 1. Shape features

| ***Features*** | ***Equations*** |
|---|---|
| Area | $A(S) = \iint I(x,y)\, dy\, dx$ |
| Perimeter | $P(S) = \int_t \sqrt{x^2(t) + y^2(t)}\, dt$ |
| Centroid | $A = \frac{1}{2}\sum_{i=0}^{n-1}(x_i y_{i+1} - x_{i+1} y_i)$ |
| Diameter | $\frac{c}{d} = \pi$ |

## 3. PERFORMANCE MEASUREMENT

In this study, the classification of the segmented region is performed using a supervised classifier named neural network. The shape features for each image are calculated and fed into the neural network to classify whether the segmented area belongs to the vertabrae or the background. The ground truth is also been provided manually by the radiologist for result validation purposes. Thus, the input layer of the neural network is directly connected to the shape features of the segmented region.

The classification is to determine whether the segmented ares is categorized as vertabrae or background. Thus, the output of the neural network is represented as: vertebrae images are represent by '0' and background images are represent as '1'.

The neural network used in this study has 3-layer; input layer, hidden layer and output layer. Figure 5 depicts a general diagram of a feed-forward 3-layer neural network. The architecture of neural network used in this experiment is as follows: the hidden layer contains 10 neurons and one node in the output layer. Sigmoid function, $\sigma(x)$ is chosen as the activation function for this neural network. The number of image samples is randomly divided into 3 parts; 60% for training, 5% for validation and 35% for testing. The training phase in neural network is perform on 6-fold validation. This is to avoid an overfitting situation in the training phase

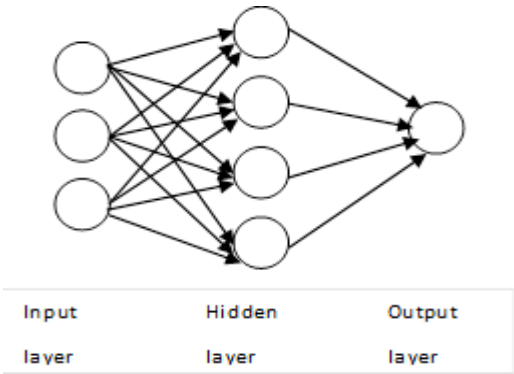


*Figure 5. General diagram of a feed forward 3-layer neural network*

After classification is performed, we can analyze the Otsu's method based on performance measurement. There are two measurement such as Receiver Operating Curve (ROC) and confusion matrix. True positive (TP) is a case that is classified as a abnormal and in reality it is a abnormal. True negative (TN) is classified as a normal case and the reality is normal. False positive (false positive, FP) is a case that is classified as a abnormal, but the reality is normal. False negative (FN) is a case that is classified as normal but in reality, is abnormal (Campilho, A. & Kamel, M. 2012).

## 4. RESULT AND DISCUSSION

The performance measurement of segmentation using both local and global thesholding methods are evaluated and compared. Both methods are tested on the same 20 MRI images databases. The results of the segmentation methods can be evaluated in qualitative and quantitative measures.

Figure 6 (a) and (b) show two MRI spine cases that are marked with the detected vertebrae using local and global thresholding methods, respectively. Qualitatively, local thresholding using Ni-black algorithm detects vertabrae more efficient compare to segmentaion by global thresholding using 6-level Otsu method. However, both segmentation methods have also falsely segmented pixels that are not vertebrae. This is due to the thresholding methods are based on the intensity of the pixels in the image.

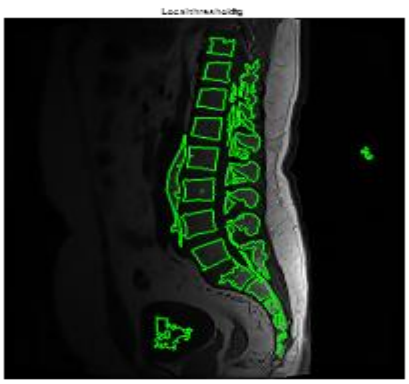

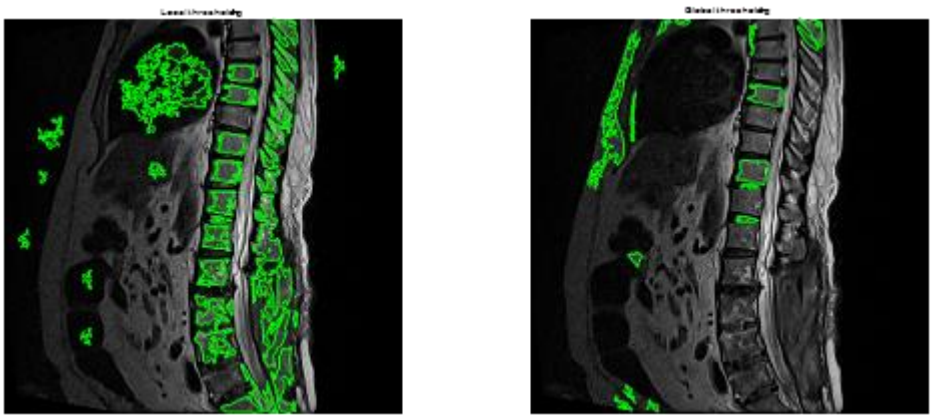

Figure 6. Segmented MRI images using (a) Ni-black local thresholding and (b) 6-level Otsu global thresholding

Qualitatively, the performance of the segmentation methods is measure using neural network classifier. Figure 7 shows the ROC of the neural network classification of the segmented vertabre using local and global thresholding methods. The results show that local thresholding segmentation method, Ni-black method, achieves accuracy of 91.4%. Whereas, when using global thresholding method, Otsu method, the classifier achieves 87.7% of classficiation accuracy.

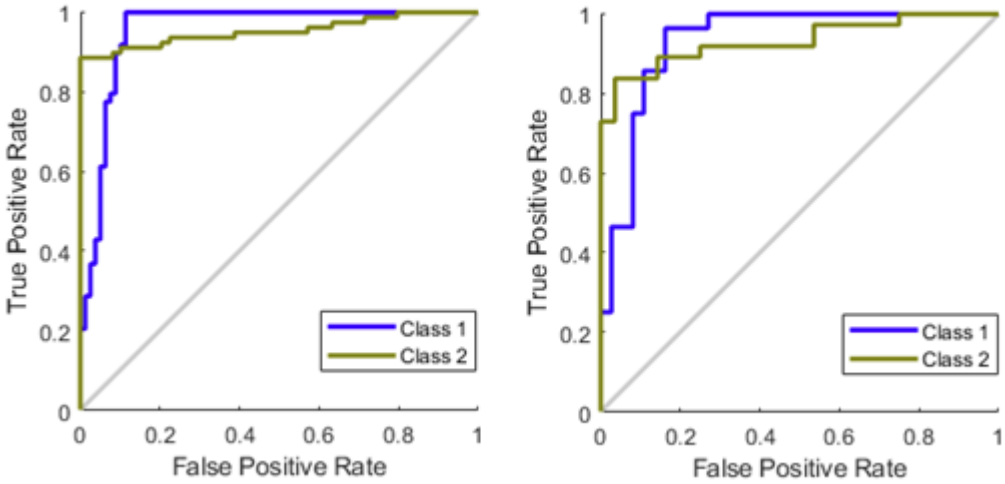


Figure 7. ROC curve for classification of fully-automated segmentation method based on (a) Ni-black local thresholding and (b) Otsu global thresholding

## 5. CONCLUSION

The preliminary result of this work shows that the choice of segmentation method in image processing technique for diagnosing MRI spine is crucial and does affect the overall performance of classification. The technique that able to precisely segment the region of interest has advantanges in extracting useful and important features, specifically to diagnose MRI spine correctly.

In future, it is aimed to explore the ability of the deep learning neural network, where the feature extraction process is automatically done in the network, without the need of segmenting the region of interest.

## References

Barbieri, P. D. *et al.* (2015) 'Vertebral body segmentation of spine MR Images using Superpixels', *IEEE 28th International Symposium on Computer-Based Medical Systems (CBMS)*, pp. 44–49.

Bazila and Mir, A. H. (2014) 'Segmentation Of Lumbar Intervertebral Discs from Spine MR Images', in *2014*

*Innovative Applications of Computational Intelligence on Power, Energy and Controls with their impact on Humanity (CIPECH)*, pp. 85–91.

Chen, J. *et al.* (2018) 'Image Thresholding Segmentation Based on Two Dimensional Histogram Using Gray Level and Local Entropy Information', *IEEE Access*, 6, pp. 5269–5275.

Chevrefils, C. *et al.* (2009) 'Texture Analysis for Automatic Segmentation of Intervertebral Disks of Scoliotic Spines From MR Images', *IEEE Transactions on Information Technology in Biomedicine*, 13(4).

Doi, K. N. (2005) 'Current status and future potential of computer-aided diagnosis in medical imaging.', *The British Journal of Radiology.*, 78, pp. 3–19.

Hirokawa, Y. *et al.* (2008) 'MRI artifact reduction and quality improvement in the upper abdomen with PROPELLER and prospective acquisition correction (PACE) technique.', *AJR American Journal of Roentgenol*, 19(14), pp. 1154–8.

Hoad, C. L. *et al.* (2001) 'A 3D MRI sequence for computer assisted surgery of the lumbar spine', *Physics in Medicine and Biology*, 46(8), pp. N213-20.

Jordon, J., Konstantinou, K. and O'Dowd, J. (2009) 'Herniated lumbar disc', *BMJ Clinical Evidence*, 2009(1118).

Michopoulou, S. (2011) *Image analysis for the diagnosis of MR Images of Lumbar spine*. University College London.

Michopoulou, S. K. *et al.* (2009) 'Atlas-Based Segmentation of Degenerated Lumbar Intervertebral Discs From MR Images of the Spine', *IEEE Transactions on Biomedical Engineering*, 56(9), pp. 2225–2231.

Peng, Z. *et al.* (2005) 'Automated Vertebra Detection and Segmentation from the Whole Spine MR Images.', *Conference of the IEEE Engineering in Medicine and Biology Society*, 3, pp. 2527–30.

Rais, N. Bin, Hanif, M. S. and Taj, I. A. (2004) 'Adaptive Thresholding Technique for Document Image Analysis', *Multitopic Conference 2004. 8th InternationalProceedings of INMIC 2004.*, pp. 61–66.

Rangayyan, R. M., Deglint, H. J. and Boag, G. S. (2006) 'Method for automatic detection and segmentation of the spinal canal in computed tomographic image', *Journal of Electronic Imaging*, 15(3).

Roberts, N., Gratin, C. and GH. Whitehouse (1997) 'MRI analysis of lumbar intervertebral disc height in young and older populations', *Journal of Magnetic Resonance Imaging*, 7(5), pp. 880–6.

Senthilkumaran, N. and Kirubakaran, C. (2014) 'Efficient Implementation of Niblack Thresholding for MRI Brain Image Segmentation', *International Journal of Computer Science and Information Technologies*, 5(2), pp. 2174–2176.